



TOMASZ TOMASZEWSKI<sup>1</sup>, MARCIN BARAN<sup>1</sup>, AGNIESZKA LASOTA<sup>2</sup>,  
IZABELLA DUNIN-WILCZYŃSKA<sup>2</sup>, BARTOSZ SAMCZYK<sup>1</sup>, IWONA MITURA<sup>2</sup>,  
JOLANTA WOJCIECHOWICZ<sup>1</sup>

## The cooperation between orthodontists and surgeons in treating facial skeletal deformities

### Abstract

Face skeletal deformities have been confusing both doctors and patients for ages. The harmony of the face exerts huge influence not only on one's psyche but also the behavior and the individual's social and professional status. In this study we present a procedure of treating skeletal malocclusion. It was performed using various orthodontic methods, like the alteration of the growth of jaws and camouflage applied in appropriate age groups. We paid special attention to the close cooperation between the orthodontist and the surgeon, which hugely facilitates curing the most complex, multi-dimensional deformities. In this study, we present our own materials concerning the effects of cooperation between two departments of Medical University of Lublin, namely the Chair and Clinic of Maxillofacial Surgery and Department of Jaw Orthopedics.

**Keywords:** skeletal deformities, orthodontic treatment, surgical treatment.

**DOI:** 10.1515/pjph-2015-0023

### INTRODUCTION

The fact that the face is one of the most important parts of the human body was recognized long time ago. Initially, the discussion focused on beauty issues and facial proportions. Right now, with attempts to improve one's face so popular, the discussion also concerns the relation between the looks of one's face and the individual's social position. It goes without saying that the face, along with its attractiveness, harmony and beauty, has some material meaning. It is the most exposed, visible body part of a human being and hugely affects the human psyche, behavior and social and professional position. People with attractive faces are typically treated better [1-3]. Both during the babyhood and childhood period, the face already plays a huge role. Babies, as well as children with a pretty, harmonious face receive more emotion from their mothers [4,5]. Adults with attractive, pretty faces are promoted more easily and more quickly, and receive better jobs. On the other hand, any irregularities in the appearance of the face or lack of harmony are negatively affecting one's personality formation, as well as their behavior and socio-professional position.

About 80% of patients affected with morphological defects in the face, decide to cure it, because they do not approve of their face traits and occlusal conditions [6,7].

Teams comprised of orthodontists and surgeons are looking to improve the esthetics and facial proportions, as well as try to reconstruct the correct occlusal conditions.

In order to achieve satisfactory and acceptable results of the orthodontic-surgeon's treatment requires:

1. Thorough diagnostics of the defect.
2. Individual treatment planning.
3. Accurate informing of the patient of benefits and the risk associated with the planned orthodontic and surgeon's treatment
4. A cooperation between the orthodontist and the surgeon at every stage of the treatment.

The orthodontist and the surgeon need to cooperate closely during all the consecutive stages of the treatment.

Severe skeletal malocclusions diagnosed on the basis of intra- and extra oral examination and cephalometric measurements different from the norm. is pointing to the need of the team orthodontic-surgeon's treatment.

The ultimate decision about the treatment should depend on two factors – the degree of malocclusion and the patient's age.

Anterio-posterior malocclusion treatment in children can be conducted by altering the growth of jaw bones (Figure 1).

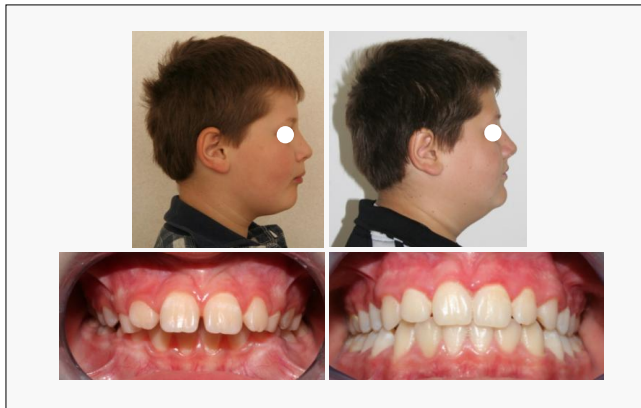
Orthopedic appliances used for this purpose put pressure on the bone indirectly, through teeth. In order to maximize the treatment effect, the treatment needs to be started before the growth spur begins. Skeletal class III malocclusions are being corrected with a face mask, which is particularly efficient in children between 7 to 12 years of age [8]. The inhibition of maxillary growth in case of class II malocclusion is performed with a headgear. However, this method is not recommended for patients with the increased vertical facial dimensions [9].

<sup>1</sup> Chair and Clinic of Maxillofacial Surgery, Medical University of Lublin, Poland

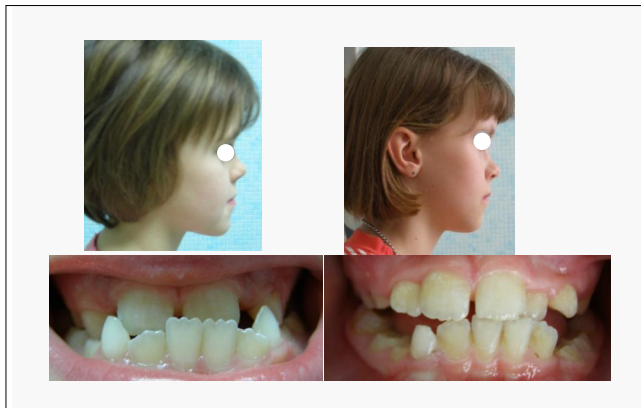
<sup>2</sup> Chair and Department of Jaw Orthopaedics, Medical University of Lublin, Poland

In children using functional appliances, in which released forces come from the muscle tension of the mandible, placed in the compulsory, healing position is other manner of growth modification. There are numerous types of such appliances available, but in order for the treatment to be successful, the patient needs to cooperate.

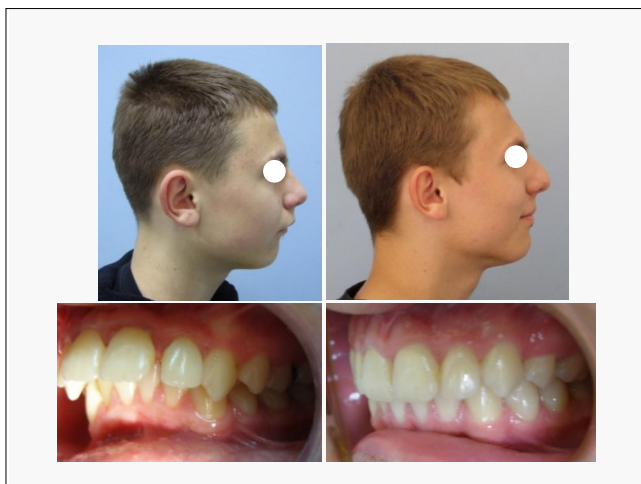
It needs emphasizing that there is no clear correlation between the severity of malocclusion and the success of the growth modification treatment [10]. In case the defect exceeds the abilities of the orthopedist or the treatment and the growth is proceeding disadvantageously, a treatment



**FIGURE 1.** Class II (maxillary and mandibular deformities) skeletal malocclusion in a child treated with growth modification.



**FIGURE 2.** Class III (maxillary and mandibular deformities) skeletal malocclusion in a child treated by growth modification, in future a planned surgical procedure.



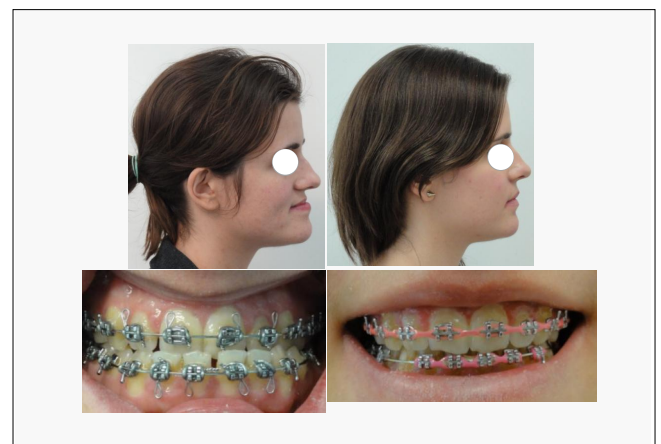
**FIGURE 3.** Class II skeletal malocclusion treated with the orthodontic camouflage with extractions of teeth.

by a team of orthopedists and surgeons is recommended [11] (Figure 2).

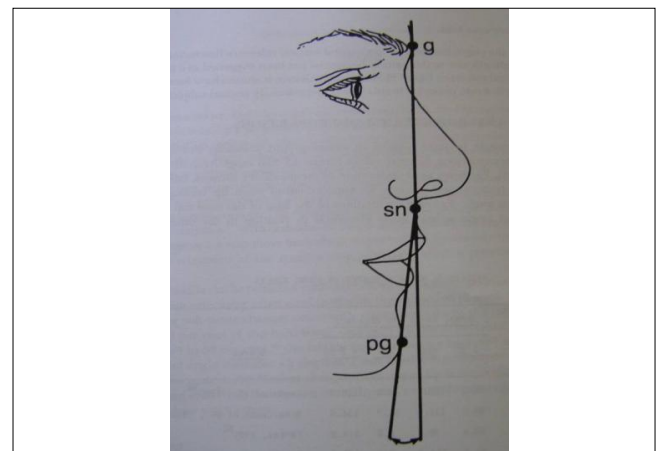
Anterio-posterior skeletal malocclusions treatment in adult patients can be done in two ways. Patients with severe malocclusion can be treated based on orthodontic camouflage (Figure 3) or categorized for the orthodontic-surgeon's treatment (Figure 4).

It is very difficult to perform an orthodontic treatment of skeletal vertical malocclusions in adult patients. There are limited possibilities of moving teeth. This forces orthodontists to qualify patients for a orthodontic-surgical treatment, even if the defects are of an average severity. The choice of a surgery method depends on the number of changes in situating the jaws and teeth, as well as the changes of the range of face soft tissues expected in the patient. Single-mandibular operations are recommended for smaller irregularities, particularly those affecting single bones. In compound, complicated cases of defects, with disturbances in a few plains, bi-mandibular treatments are necessary [11].

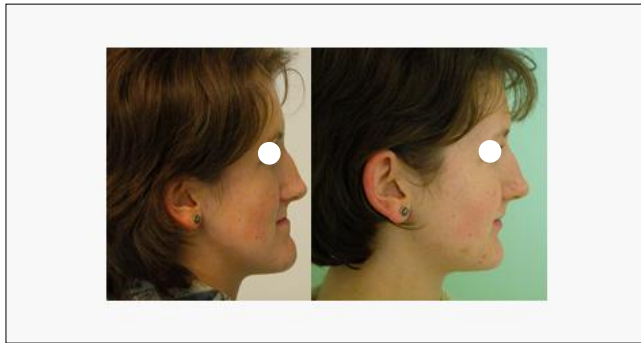Anterio-posterior revision of the maxillary and the mandible position requires the doctors to analyze the facial convexity angle in the facial profile. This angle shows the correct antero-posterior location of Pogonion point, when maxilla is situated in the correct spot (Figure 5). An evaluation of the nasal-labial angle is also essential.



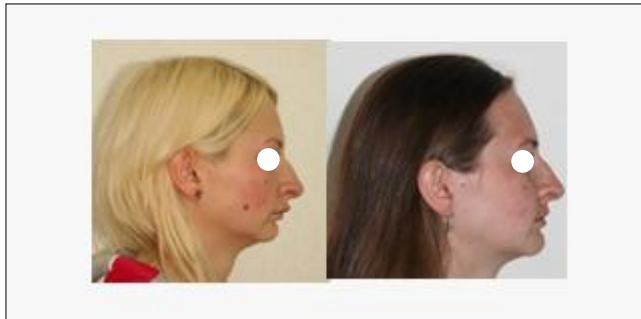
**FIGURE 4.** Class II skeletal malocclusion treated with orthodontic-surgical method. Surgeons performed: maxillary osteotomy Le Fort I – protrusion and the turnover of the maxilla left, bilateral sagittal split osteotomy of the mandible – moving back and the rotation of the mandible to the right.



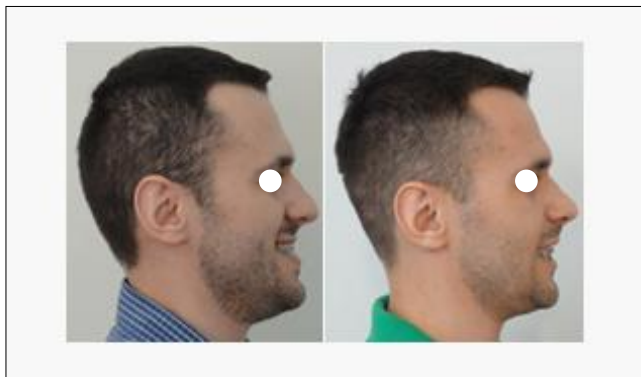
**FIGURE 5.** Facial convexity angle.



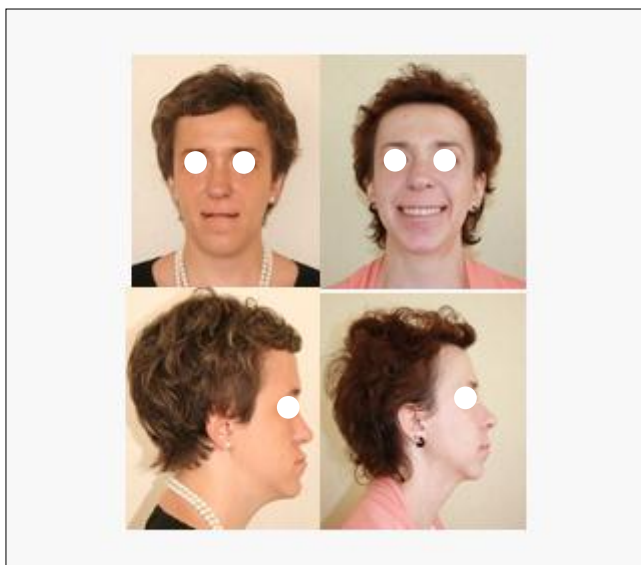
**FIGURE 6.** Class III skeletal deformity. Bilateral sagittal split mandibular osteotomy (BSSO) – retraction of mandible.



**FIGURE 7.** Class II skeletal deformity. Bilateral sagittal split mandibular osteotomy (BSSO) – protrusion of the mandible.



**FIGURE 8.** Class III skeletal deformity. Osteotomy Le Fort I – maxillary protrusion and turnover into left.



**FIGURE 9.** Patient with class III skeletal deformity. High osteotomy Le Fort I – maxillary protrusion, maxillary impaction in the back segment and BSSO – retracting of the mandible with the posterior rotation.

Moving the mandible back during bilateral sagittal split osteotomy also causes big changes in the face structure and soft tissues appearance. Lower lip, labio-mental sulcus and the soft tissue Pogonion point are retracted. In about 90%, they are following the moved mandible (Figure 6).

Later, the protrusion of the mandible during its osteotomy causes a 100% copying of the bone move by soft tissues. The biggest changes are happening in the lower lip, which can change the way it is situated, as well as labio-mental sulcus and the soft tissue pogonion point [12,13].

Maxillary Le Fort I osteotomy, along with a protruded maxilla, makes the tip of the nose go up and ahead. The nasal-labial angle is increasing at every millimeter of the protrusion, while the upper lip moves ahead, many a time becoming shorter. This needs to be remembered by anyone performing surgical procedures.

Positioning the maxilla in a vertical way needs to be done in a way that enables the exposition of upper incisors from under the upper lip in the rest and when the patient is smiling.

In case the maxilla is too short and retracted, a lack of the normal exposition of upper incisors, the red of the upper lip and the suborbital surrounding is appearing which is flattened and not very prominent. However, Pogonion point because of the rotation of the mandible is prominent. In these cases, osteotomy Le Fort I procedure and the downward maxillary reposition improve the facial proportions and of the face and exposition of upper incisors (Figure 9).

Maxillary intrusion is performed in patients with increased vertical dimension. Shortening the vertical dimension of the jaw, causes an elevation of the tip of the nose and the Subnasale point at about 20% towards the bone shift, lifting the Labiale Superius point up about 30%, shortening the upper lip of 20-40%, expanding the base of the nose and making cheeks bulge. Simultaneously, it enables the anterior rotation of the mandible which moves ahead the Pogonion point, and the soft tissue Pogonion point c 90% will imitate the move of the skeletal point (Figure 10).

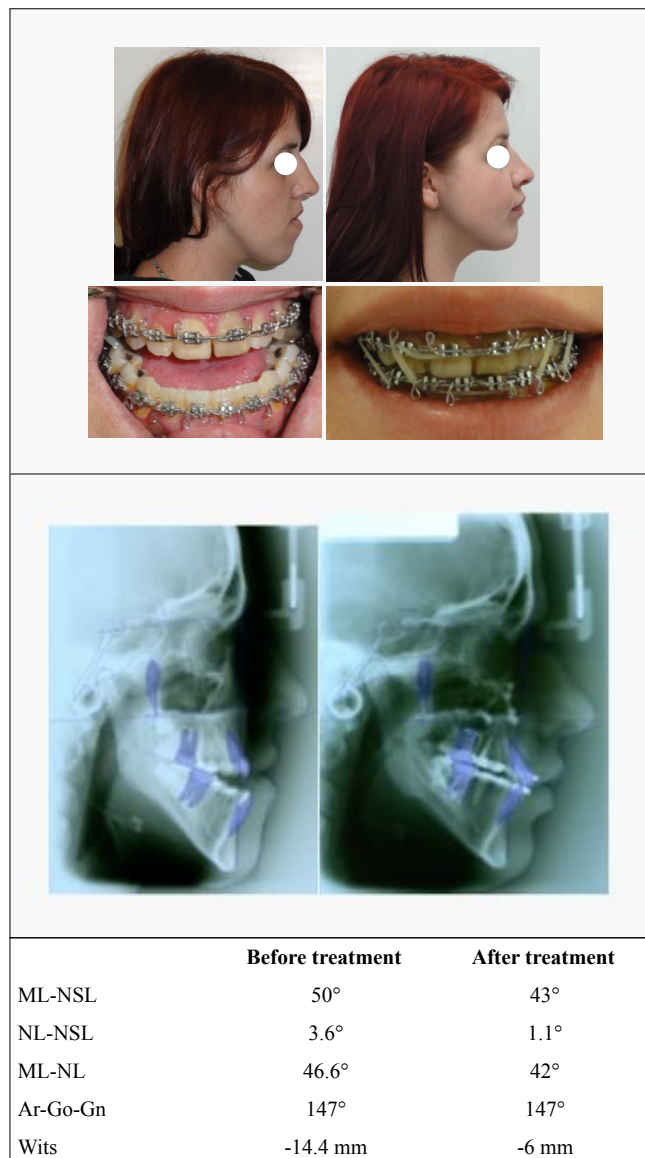As it can be seen in the attached pictures, there is a huge change in one's facial esthetics: face's proportion changes and the occlusal relations are checked with chosen cephalometric measurements. The decrease of the mandible line (ML) and maxillary plane (NL) angles with anterior cranial fossa plane (NSL) results in a decrease of anterior facial height and correction of skeletal open bite. Reduction in Wits measurement describes an improvement in the antero-posterior relation, which was achieved by these changes, together with mandibular backward movement.

The cooperation between the Chair and Clinic of Maxillofacial Surgery and Chair and Department of Jaw Orthopedics in Medical University of Lublin in treatment of skeletal deformities has been going on since 1993. It started with basics of contemporary principles of decompensation and fixed orthodontic appliances for routine procedure in orthognathic patients preparing for the surgical treatment.

Orthognathic surgery is mainly concerned with procedures like: bilateral sagittal split mandibular osteotomy, osteotomy of Le Fort I type and genioplastics. [14,15]. Since 2007, the jaws osteotomy procedure has been performed with the application of "piezosurgery", at Maxillofacial Surgery



Clinic in Lublin [16]. Our own observations of this method are pointing at the greater precision of the osteotomy, limiting the invasiveness of the treatment, additional preservation of soft tissues, special usefulness in the multi-segmental osteotomy of facial bones, in the preceding osteotomy – osteodistraction e.g. with the application of extra oral distractor of RED (Rigid External Distraction) system and treatments corticotomy, which in a meaningful way facilitate orthodontic proceedings at the stage of the decompensation of the malocclusion [17].



**FIGURE 10.** Class III skeletal deformity. Osteotomy Le Fort I – maxillary protrusion, shortening in the front segment, correction of the occlusion oblique plain, bilateral sagittal split mandibular osteotomy – retracting of the mandible and its anterior rotation.

## REFERENCES

- Dion K, Berscheid E, Walster E. What is beautiful is good. *J Pers Soc Psychol.* 1972;24:285-90.
- Langlois JH, Kalakanis L, Rubenstein AJ, et al. Maxims or myths of beauty. A meta-analytic and theoretical review. *Psychol Bull.* 2000;126:350-423.
- Senior C, Thomson K, Badger J, Butler MJ. Interviewing strategies in the face of beauty. A psychophysiological investigation into the job navigation process. *Ann N Y Acad Sci.* 2007;1118:142-62.
- Langlois JH, Ritter JM, Casey RJ, et al. Infant attractiveness predicts maternal behaviors and attitudes. *Dev Psychol.* 1995;31:464-72.
- Ritter JM, Casey RJ, Langlois JH. Adults responses to infantis varying in appearance of age and attractiveness. *Child Dev.* 1991;62:68-82.
- Choi WS, Lee S, McGrath C, Samman N. Change in quality of life after combined orthodontic-surgical treatment of dentofacial deformities. *Oral Surg Oral Med.* 2010;109:46-51.
- Johnston C, Hunt O, Burden D, et al. Self-perception of dentofacial attractiveness among patients requiring orthognathic surgery. *Angle Orthod.* 2010;80:361-6.
- Takada K, Petdachai S, Sakaduda M. Changes in dentofacial morphology in skeletal Class III children treated by a modified maxillary protraction headgear and a chin cup: a longitudinal cephalometric appraisal. *Eur J Orthod.* 1993;15:211-21.
- Freeman CS, Mc Namara JA Jr, Bacetti T, et al. Treatment effects of the bionator and high-pull facebow combination followed by fixed appliances in patients with increased vertical demensions. *Am J Orthod Dentofacial Orthop.* 2007;131:184-95.
- Tulloch JF, Phillipps C, Koch G, Proffit WR. The effect of early intervention on skeletal pattern in Class II malocclusion: a randomized clinical trial. *Am J Orthod Dentofac Orthop.* 1997;111:391-400.
- Proffit WR, White RP, Sarver DM. Contemporary treatment of dentofacial deformity. St. Louis: Mosby; 2003.
- Lines PA, Steinhauser EW. Soft tissue changes in relationship to movement of hard structures in orthognathic surgery: a preliminary report. *J Oral Surg.* 1974;32:891-6.
- Wolford LM, Hilliard FW. The surgical-orthodontic correction of vertical dentofacial deformities. *J Oral Surg.* 1981;39:883-97.
- Dal Pont G. Retromolar osteotomy for correction of prognathism. *J Oral Surg.* 1961;19:42-7.
- Epker BN. Modifications in the sagittal split osteotomy of the mandible. *J Oral Surg.* 1977;35:157-62.
- Gruber RM, Kramer FJ, Merten HA, Schliephake H. Ultrasonic surgery-an alternative way in orthognathic surgery of the mandible. A pilot study. *Int J Oral Maxillofac Surg.* 2005;34:590-3.
- Tomaszewski T, Dobieżyńska B. Piezosurgery-alternative new way in orthognathic surgery. *Pol J Environ Stud.* 2007;16:379-81.

### Corresponding author

Izabella Dunin-Wilczyńska  
7 Karmelicka Str., 20-081 Lublin  
Tel. 81 528-79-40  
E-mail: izabela.dw@umlub.pl

Photographic documentation supplied by the Authors.